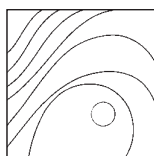


# Efficacy of Er,Cr:YSGG Laser Application in Nonsurgical Treatment of Peri-implantitis: A Human Randomized Controlled Trial



Philip Kang, DDS<sup>1</sup>  
 Elena Sanz-Mirallés, DDS, MS, MSc, PhD<sup>1</sup>  
 Jessica Li, DDS, MS<sup>1</sup>  
 Eric Linden, DMD, MSD, MPH<sup>1</sup>  
 Fatemeh Momen-Heravi, DDS, MS, PhD, MPH<sup>1</sup>

*This investigation was designed to evaluate the efficacy of an erbium, chromium-doped yttrium, scandium, gallium and garnet (Er,Cr:YSGG) laser (laser group) compared to conventional mechanical debridement (control group) in the treatment of peri-implantitis. In a double-blinded, randomized, controlled clinical trial, 32 patients with 88 implants with peri-implantitis were randomly assigned to either group. Statistical analyses were performed at 9 months for both groups. The laser-treated group showed a statistically significant reduction in probing depth (PD) compared to the control group ( $P = .04$ ), but no statistically significant differences were observed for clinical attachment level gain ( $P = .29$ ) or reduction of bleeding on probing ( $P = .09$ ). In the subgroup analysis, mandibular single implants with screw-retained restorations treated with Er,Cr:YSGG demonstrated a statistically significant decrease in PD ( $P < .05$ ) compared to all other groups. A complete resolution of peri-implantitis was achieved in 21% of implants in the test group and 5% of implants in the control group. Er,Cr:YSGG laser is an efficacious therapeutic tool to treat peri-implantitis, achieving greater PD reduction than conventional mechanical debridement alone. Er,Cr:YSGG laser also showed increased benefits in the treatment of mandibular, screw-retained, and single-unit implants compared to the sole use of conventional mechanical debridement. Int J Periodontics Restorative Dent 2023;43:e1–e9. doi: 10.11607/prd.6384*

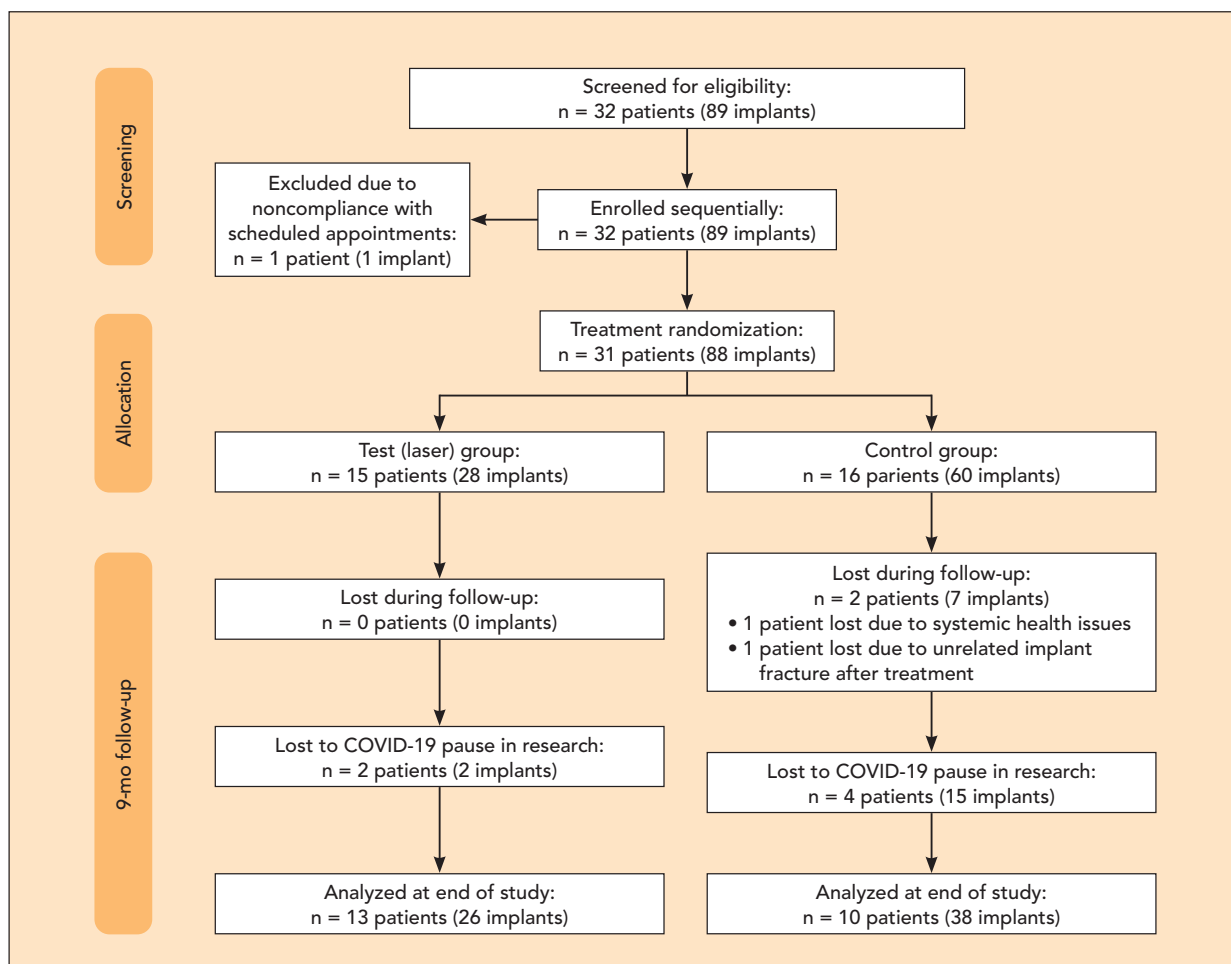
<sup>1</sup>Division of Periodontics, Section of Oral, Diagnostic and Rehabilitation Sciences, Columbia University College of Dental Medicine, New York, New York, USA.

Correspondence to: Dr Fatemeh Momen-Heravi, Columbia University College of Dental Medicine, 622 W 168th St, New York, NY 10032, USA. Email: pyk2104@cumc.columbia.edu  
 Dr Elena Sanz-Mirallés, 6303 Bannockburn Dr, Bethesda, MD 20817, USA.  
 Email: esanzmiralles@gmail.com

Submitted May 16, 2022; accepted August 10, 2022.  
 ©2023 by Quintessence Publishing Co Inc.

Despite the different treatment modalities for peri-implant mucositis and peri-implantitis, there still is an unmet need for a predictable and noninvasive treatment.<sup>1</sup> A variety of surgical modalities, such as conventional resective and regenerative surgeries, chemical agents, implantoplasty, and lasers, have been proposed to treat peri-implantitis.<sup>2–4</sup> While searching for an effective noninvasive method to detoxify contaminated implant surfaces remains challenging, the use of lasers has gained popularity in recent years among the scientific community and patients. Various dental lasers have emerged as adjunct tools to be used in multiple clinical applications. Therapeutically, lasers are used extensively in treating various forms of periodontal and peri-implant diseases, and their effectiveness is hypothesized to be through enhanced disinfection and promotion of better wound healing that may lead to successful regeneration around both ailing teeth and implants.<sup>5–9</sup>

Lasers have been used mostly as an adjunctive therapy to traditional approaches. The most critical determinant of a laser's effect on living tissue is the wavelength.<sup>10</sup> The most common range of wavelengths used in periodontics and implant therapy spans from 400 to 10,600 nm. Different laser wavelengths have been used for the treatment of peri-implantitis,



**Fig 1** Flowchart of patient inclusion throughout the study period.

including diode laser (450 to 1,064 nm), Nd:YAG (1,064 nm), Er:YAG (2,940 nm), Er,Cr:YSGG (2,780 nm), and CO<sub>2</sub> (9,300 to 10,600 nm).<sup>10</sup> In particular, erbium-based lasers such as Er,Cr:YSGG have shown to possess several advantages: Their wavelength is poorly absorbed by titanium (therefore minimizing thermal damage of the implant surface),<sup>9</sup> ablates calculus effectively,<sup>11–13</sup> and has been shown to reestablish bone-to-implant con-

tact.<sup>14</sup> However, there is limited evidence on their use as an adjunct to conventional mechanical debridement. Moreover, it is yet to be determined if the potential superior decontamination of the implant surface translates into superior clinical results based on different anatomical sites and implant characteristics. The goal of this randomized interventional study is to compare the efficacy of the Er,Cr:YSGG laser's Repair Implant Protocol to the con-

ventional mechanical debridement for the treatment of peri-implantitis.

## Materials and Methods

### Study Design

The study design was a double-blind randomized clinical trial (NCT03544515). An Institutional Review Board at Columbia University approved the study protocol.

All patients signed written informed consent, and the CONSORT guidelines for clinical trials were followed (Fig 1). Patients of Columbia University College of Dental Medicine Postgraduate Periodontics Clinic in New York were recruited. Inclusion criteria were as follows: (1) having at least one implant with a fixed restoration; (2) diagnosed with peri-implantitis (ie, presenting with at least one site with bleeding on probing [BOP] and/or suppuration on gentle probing); (3) pocket depth (PD) > 5 mm; (4) presence of bone loss beyond crestal bone level changes resulting from initial bone remodeling,<sup>15</sup> extending no more than one third of the implant length; (5) medically healthy (diabetic patients were included if HbA1c ≤ 7%); and (6) no history of systemic antibiotics or periodontal treatment other than maintenance in the previous 3 months. Patients were excluded from the study if they were pregnant or had a smoking habit.

Randomization was performed at the patient level. Based on the mean PD difference reported between the laser and control groups in a previous laser study,<sup>16</sup> 10 patients per treatment arm gave 89% power (at an alpha of .05) to detect a difference of  $1.72 \pm 1.13$  mm in PD between the groups. For possible attritions, a final sample of 16 patients per treatment arm was established. Patients were enrolled sequentially and assigned a number from 1 to 32, then randomized to treatment groups.

The primary outcome was the change in mean PD at each implant site. Secondary outcomes included

changes in clinical attachment level (CAL), radiographic bone level (RBL), BOP, and Plaque Index (PI). The following subgroup analyses were also performed to account for other local predisposing factors for peri-implantitis: screw- vs cement-retained prosthesis, maxillary vs mandibular implants, and single-unit implants vs multiple splinted implants.

### *Clinical and Radiographic Measurements*

Clinical and radiographic exams were completed at baseline (before treatment) and 9 months posttherapy. PD, CAL (rounded up to the nearest 1 mm), BOP (present or absent), and PI (present or absent) were registered with a periodontal probe at six sites per implant as primary variables and at six sites per tooth as secondary variables. The implant-abutment connection was used as the reference point to calculate CAL. Periapical radiographs were standardized with the use of a bite block. Two examiners (P.K., E.S.M.) utilized MiPACS Dental Enterprise Viewer (Medicor Imaging) using a calibrated and reproducible approach to obtain the measurements. The interexaminer reliability for radiographic measurements was calculated based on the Bland-Altman statistical method, and the average mean difference between examiners was 0.16 mm. A composite score of disease resolution—determined as the absence of deep PDs ( $\geq 5$  mm), and no BOP, suppuration, or additional bone loss—was constructed to compare the two groups.<sup>17</sup>

### *Treatments*

Incisions and flaps were not made, and no prosthetic components were removed.

Implants in the control group were mechanically debrided along each thread with an ultrasonic scaler (Cavitron, Dentsply Sirona) with standard tips (Ultrasonic Insert, Dentsply Sirona), hand instrumentation (Gracey 13/14 and 15/16 and universal 4R/4L curettes, Henry Schein), and sham laser therapy (laser tip applied but not activated) around the implant sulcus.

Implants in the test group were treated following the Repair Implant Protocol for the Waterlase iPlus 2.0 Er,Cr:YSGG laser (Biolase) (Table 1).

All patients returned for follow-ups and oral hygiene instructions at 1 week and 3, 6, and 9 months postoperative. At the 3-month and 6-month follow-ups, patients received supragingival cleaning on all teeth and implants.

### *Statistical Analysis*

Data analysis included all randomized patients with available 9-month follow-up results. Both patient-level and implant-level analyses were performed. A mixed model analysis of covariance (ANCOVA) and F-tests were used for all hypothesis testing. Student t test or Wilcoxon rank was used for pairwise comparisons. Multiple comparisons were corrected by Dunnett's multiple comparison test. Data are presented as mean  $\pm$  standard deviation or mean  $\pm$  95% CI (confidence interval).

**Table 1 Repair Implant Protocol Steps and Laser Parameters**

Steps	Purpose	Tip	Power	Pulse energy	Pulse duration	Frequency	Air/water output, %
Outer deepithelialization	Removal of outer pocket gingival epithelium	RFPT5-5	1.5 W	50 mJ	60 $\mu$ s	30 Hz	40/50
Deepithelialization and reflection	Creation of mini flaps	RFPT5-5	1.5 W	50 mJ	60 $\mu$ s	50 Hz	40/50
Pocket debridement	Scaling and root planing	Ultrasonic and hand instruments	N/A	N/A	N/A	N/A	N/A
Implant decontamination	Cleaning of the implant surface	SFTP8-18	1.5 W	30 mJ	60 $\mu$ s	30 Hz	40/50
Decortication	Bone recontouring and induction of bleeding	MZ5-15	2.5 W	80 mJ	60 $\mu$ s	30 Hz	70/80
Final sulcular debridement	Removal of residual debris and inducing blood coagulation	RFPT5-14	1.5 W	50 mJ	60 $\mu$ s	50 Hz	10/10
Pressure w/ 2 $\times$ 2-mm wet gauze for 5 min	Stabilization of the surgical field	N/A	N/A	N/A	N/A	N/A	N/A

All tips were manufactured by Biolase.

A  $P$  value  $< .05$  was considered statistically significant.

## Results

The demographics and baseline implant characteristics are reported in Table 2. Of the 32 patients initially enrolled in the study, 3 were excluded before the end of the study due to noncompliance with the follow-up appointments, systemic health issues, and unrelated posttreatment implant fracture. Further, 6 patients (4 in the control group and 2 in the test group; comprising 17 implants) could not complete the study due to the COVID-19 pause in research activity. A total of 23 patients (13 in the test group and 10 in the control group;  $n = 64$  total implants) completed the full 9-month evaluation (Fig 1).

After adjusting for baseline values and subjects by a mixed-model ANCOVA, the laser-treated implants showed a statistically significant reduction in PD compared to the control group ( $P = .04$ ). No statistically significant differences in PI, BOP, or CAL were observed after adjusting for covariates. There was no statistically significant difference between the two groups (Table 3). The mean (95% CI) PD reduction of treated implants was  $-0.73$  mm ( $-1.17$  mm,  $-0.28$  mm) for the control group and  $-1.36$  mm ( $-1.96$  mm,  $-0.77$  mm) for the test group. Considering the composite outcome of disease resolution, 5% of implants in the control group and 21% of implants in the test group showed complete resolution of diseases.

Figure 2 illustrates the results of the subgroup analysis. After ad-

justing for subjects, screw-retained implants in the test group showed a statistically significantly greater PD reduction than the control group ( $P = .01$ ; mean difference [95% CI]:  $-0.95$  mm [ $-1.73$ ,  $-0.17$  mm]) (Fig 2a). Mandibular implants treated with the laser demonstrated a statistically significant decrease in PD at 9 months compared to maxillary implants ( $P = .03$ ; mean difference [95% CI]:  $-0.83$  mm [ $-1.58$ ,  $-0.08$  mm]) and they also demonstrated a statistically significant decrease in PD at 9 months compared to the control group ( $P = .002$ ; mean difference [95% CI]:  $-1.11$  mm [ $-1.78$ ,  $-0.44$  mm]) (Fig 2b). Single-unit implants treated with the laser showed a statistically significant decrease in PD compared to the control group ( $P = .01$ ; mean difference [95% CI]:  $-0.79$  mm [ $-1.40$ ,  $-0.17$  mm]) (Fig 2c).

**Table 2 Baseline Patient and Implant Characteristics**

	Control	Test	Total
<b>Patient data</b>			
Patients, n	16	15	31
Age, mean $\pm$ SD	67.19 $\pm$ 9.26 y	62.53 $\pm$ 7.12 y	64.93 $\pm$ 8.49 y
<b>Gender, n (%)</b>			
Male	4 (25%)	2 (13%)	6
Female	12 (75%)	13 (87%)	25
T2DM (HBA1C < 7), n	2	1	3
Baseline radiographic bone loss, mean $\pm$ SEM	3.4 $\pm$ 1.7 mm	3.8 $\pm$ 0.31 mm	3.4 $\pm$ 0.2 mm
<b>Implant data</b>			
<b>Location, n (%)</b>			
Maxillary	39 (65.0%)	20 (71.4%)	59
Mandibular	21 (35.0%)	8 (28.6%)	29
Total	60 (100%)	28 (100%)	88
<b>Prosthesis type, n (%)</b>			
Single crowns	18 (30.0%)	17 (60.7%)	35
Splinted crowns	42 (70.0%)	11 (39.3%)	53
Total	60 (100%)	28 (100%)	88
<b>Retention type, n (%)</b>			
Screw-retained	19 (31.6%)	8 (38.0%)	27
Cement-retained	41 (68.4%)	20 (62.0%)	61
Total	60 (100%)	28 (100%)	88

HBA1C = hemoglobin A1c; SEM = standard error of the mean; T2DM = type 2 diabetes.  
The total number of implants and patients includes data from all randomized patients (n = 31).

Based on the radiographic analysis, the mean change in mesial sites was  $-0.02$  mm (95% CI:  $-0.27$ ,  $0.24$  mm) in the test group and was  $0.17$  mm (95% CI:  $-0.11$ ,  $0.45$  mm) in the control group ( $P = .35$ ). The mean bone level change at distal sites was  $-0.10$  mm (95% CI:  $-0.41$ ,  $-0.21$  mm) in the test group and was  $-0.03$  mm (95% CI:  $-0.25$ ,  $0.19$  mm) in the control group ( $P = .71$ ). No adverse event was observed in either group.

## Discussion

This randomized controlled clinical trial compared the nonsurgical treatment of peri-implantitis using the Er,Cr:YSGG laser's Repair Implant Protocol to the sole use of conventional debridement using curettes and ultrasonic devices. In the present study, both examiners and patients were blinded to the treatment groups to eliminate potential biases. Patient blinding

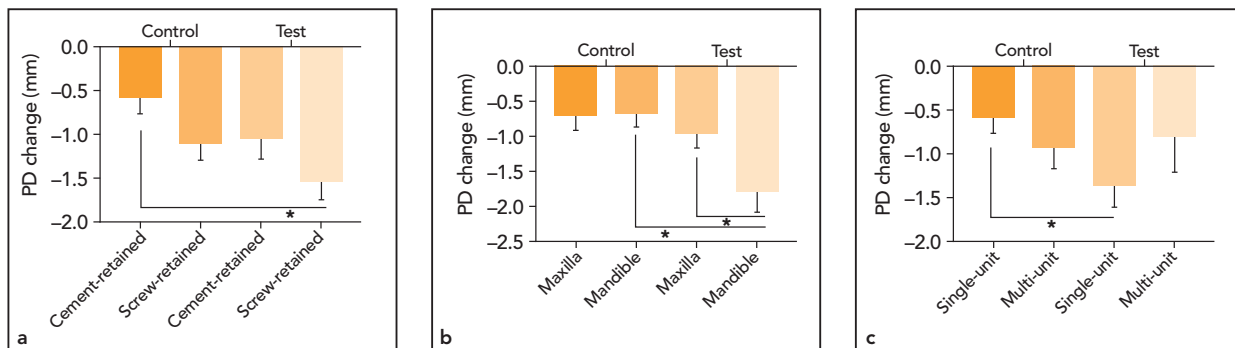
was achieved by using a sham laser without laser activation. The results at 9 months showed a statistically significant PD reduction in patients who received Er,Cr:YSGG laser treatment compared to the control group. Analysis based on peri-implantitis treatment success criteria (absence of deep PDs, no BOP, and no additional bone loss) showed that a higher proportion of implants in the test group (21%) achieved complete resolution of

**Table 3 Mean Baseline and 9-Month Periodontal and Peri-implant Parameters**

Parameter by group	Baseline	9 mo	Change	<i>P</i> <sup>a</sup>
Probing depth, mm				
Test	4.9 (4.4, 5.3)	3.6 (3.2, 4.1)	−1.36 (−1.96, −0.77)	.04
Control	4.7 (4.3, 4.9)	4.0 (3.6, 4.3)	−0.73 (−1.17, −0.28)	
Clinical attachment level, mm				
Test	5.7 (5.1, 6.2)	4.5 (3.9, 5.1)	−1.2 (−1.97, −0.36)	.29
Control	5.2 (4.9, 5.5)	4.3 (4.0, 4.6)	−0.90 (−1.34, −0.47)	
Bleeding on probing, %				
Test	81 (69, 94)	45 (23, 67)	−36 (−61, −1)	.09
Control	71 (55, 87)	51 (40, 62)	−20 (−37, −2)	
Plaque Index, %				
Test	55 (32, 77)	26 (10, 42)	−29 (−54, −2)	.14
Control	64 (48, 79)	34 (17, 50)	−30 (−50, −8)	
Radiographic bone loss, mm				
Test	3.80 (3.18, 4.42)	3.85 (3.26, 4.44)	0.05 (−0.80, 0.91)	.89
Control	3.37 (2.98, 3.76)	3.39 (2.95, 3.84)	0.02 (−0.56, −0.61)	

Data are presented as mean (95% CI).

<sup>a</sup>P values were determined according to ANCOVA to test the null hypothesis that the response is equal between the test and control groups, controlling for implant baseline values.



**Fig 2** Subgroup analyses were performed to account for other local predisposing factors for peri-implantitis. Asterisks indicate statistically significant differences ( $P < .05$ ). Data are reported as the mean  $\pm$  SEM (standard error of the mean) probing depth changes in the test (Er,Cr:YSGG laser) and control groups, comparing (a) maxillary vs the mandibular implant location, (b) single-unit vs multi-unit implants, and (c) screw-retained vs cement-retained implants.

the diseases compared to the control group (5%). These results indicate the superiority of Er,Cr:YSGG laser treatment compared to the conventional debridement meth-

od alone in the treatment of peri-implantitis. Interestingly, in the subgroup analysis, there was a higher efficacy of Er,Cr:YSGG laser treatment for mandibular sin-

gle implants with screw-retained restorations.

The present study used the only commercially available Er,Cr:YSGG laser. The availability

of literature on Er,Cr:YSGG lasers is limited. However, both Er:YAG and Er,Cr:YSGG lasers operate in the region of the major absorption peak for water, and physical and biologic performances are clinically comparable.<sup>10</sup> Erbium lasers appear to be effective for soft and hard tissue ablation, without causing adverse thermal damage, and have positive effects on the healing process.<sup>18</sup> These erbium lasers can be effective for debridement of periodontally and peri-implant diseased tissues, bacterial reduction, and calculus removal in a nonsurgical approach.<sup>11–13,19–21</sup> In particular, Er,Cr:YSGG treatment resulted in a significant reduction of PDs and improved CALs in moderate periodontitis patients.<sup>22</sup> Despite the conclusion from the American Academy of Periodontology's Best Evidence Consensus systematic review<sup>23,24</sup> which stated that the body of evidence was inadequate on the efficacy of laser therapy, more promising outcomes have been made available in recent years. Klokkevold et al reported their 12-month results after comparing the adjunctive Er,Cr:YSGG laser therapy with scaling and root planing (SRP) vs SRP alone in the treatment of moderate to severe periodontitis, concluding that adjunctive Er,Cr:YSGG laser therapy may offer advantages for treating deeper ( $\geq 7$  mm) pockets.<sup>25</sup> In a multicenter, randomized, masked, and controlled study, Clem et al demonstrated comparable clinical outcomes between an Er,Cr:YSGG group and a minimally invasive surgical technique group.<sup>8</sup>

In many aspects, peri-implantitis is similar to periodontitis; however, the roughness and the variability in the macro- and microdesigns of the implant surfaces makes it more challenging to decontaminate them as compared to teeth.<sup>26</sup> In vitro studies also have shown that erbium lasers are capable of removing bacterially infiltrated oxide layers on implants without damaging the implant surface or the adjacent supporting bone.<sup>9,21</sup> Histologic studies have reinforced these observations, demonstrated the decontamination properties of erbium-based lasers, and provided evidence of osseointegration after laser treatment.<sup>14,27</sup>

The present study assessed the changes in clinical parameters at 9 months posttherapy. Although improvement was seen with both the laser treatment and mechanical debridement alone, a statistically significant PD reduction was seen in patients who received the Er,Cr:YSGG laser treatment. While most of the focus is on the implant surface decontamination, the variations and other aspects of specific laser protocols should not be overlooked. For example, in the present study, the protocol included minor osseous recontouring steps that might have positively influenced the treatment outcome in addition to the decontamination. Additionally, the change in soft tissue profiles with more firmness after laser therapy could have contributed to the PD reduction. There was no significant difference in BOP and CAL.

Patient-level randomization was also performed. In multifactorial diseases such as peri-implantitis,

site-level observations are not independent because they are nested within the tooth level and patient level. Study designs that overlook this multilevel structure and do not consider patient-level codependencies might report potentially biased estimations and misinterpretations.<sup>14</sup> When evaluating the progression of periodontal disease and peri-implantitis, one should consider the interrelated and biologic codependencies in those diseases and consider the patient as the unit of analysis.

In addition to the primary assessments, the present study also performed three subgroup analyses (screw- vs cement-retained prostheses, maxillary vs mandibular implants, and single-unit implants vs multiple splinted implants) to account for other local predisposing factors for peri-implantitis. The analysis revealed that mandibular single implants restored with screw-retained restorations and treated with a laser showed a statistically significant decrease in PD at 9 months compared to all other groups ( $P < .05$ ). The superior effects could be attributed to a variety of factors that were not measured in the present study, such as the better cleansability around single restorations, lack of residual cements near screw-retained crown margins, the amount of keratinized tissue, the thickness of soft and hard tissues, and the position of the implant.

The present study has several limitations. Although several studies reported less postoperative morbidity with lasers,<sup>8,11,12,22,25</sup> patient-related outcomes have not yet been



collected for this study. Because this is an essential aspect of every periodontal treatment, future research and clinical studies should include information regarding patient perception and quantification of post-operative sensations following laser treatment. Another limitation is the relatively short follow-up time and limited sample size. In spite of the efforts to follow up with patients for 9 months, 6 patients could not be evaluated due to COVID-19 disruption in research activities. The lack of a cost-benefit analysis for laser treatment is another limitation. Longer follow-ups and studies with larger sample sizes are recommended to identify other factors that affect the response to laser treatment and other peri-implantitis treatment modalities. As laser treatment for peri-implantitis imposes added cost and a considerable amount of time, this should be taken into consideration before clinical decision-making. Future studies must also address the efficacy of the laser treatment for peri-implantitis concerning the cost-effectiveness.

## Conclusions

The adjunctive use of an Er,Cr:YSGG laser for the nonsurgical treatment of peri-implantitis led to greater PD reductions than mechanical debridement alone, but no additional benefits were seen for CAL gain or BOP reduction. The Er,Cr:YSGG laser also showed increased benefits in the treatment of mandibular, screw-retained, and single-unit implants.

## Acknowledgments

A grant from Biolase funded the study. The authors declare no conflicts of interest.

## References

1. Lindhe J, Meyle J; Group D of European Workshop on Periodontology. Peri-implant diseases: Consensus report of the sixth European workshop on periodontology. *J Clin Periodontol* 2008;35:282–285.
2. Renvert S, Polyzos IN. Clinical approaches to treat peri-implant mucositis and peri-implantitis. *Periodontol* 2000 2015;68:369–404.
3. Renvert S, Roos-Jansåker AM, Claffey N. Non-surgical treatment of peri-implant mucositis and peri-implantitis: A literature review. *J Clin Periodontol* 2008;35(suppl 8):305–315.
4. Heitz-Mayfield LJ, Mombelli A. The therapy of peri-implantitis: A systematic review. *Int J Oral Maxillofac Implants* 2014;29(suppl):325–345.
5. Chambrone L, Ramos UD, Reynolds MA. Infrared lasers for the treatment of moderate to severe periodontitis: An American Academy of Periodontology best evidence review. *J Periodontol* 2008;89:743–765.
6. Nevins ML, Camelo M, Schupbach P, Kim SW, Kim DM, Nevins M. Human clinical and histologic evaluation of laser-assisted new attachment procedure. *Int J Periodontics Restorative Dent* 2012;32:497–507.
7. Yukna RA, Carr RL, Evans GH. Histologic evaluation of an Nd:YAG laser-assisted new attachment procedure in humans. *Int J Periodontics Restorative Dent* 2007;27:577–587.
8. Clem D, Heard R, McGuire M, et al. Comparison of Er,Cr:YSGG laser to minimally invasive surgical technique in the treatment of intrabony defects: Six-month results of a multicenter, randomized, controlled study. *J Periodontol* 2021;92:496–506.
9. Linden E, Cobb CM, Fletcher P, Zhao D. SEM evaluation of the effects of laser-mediated implant surface decontamination: An in situ human pilot study. *Int J Periodontics Restorative Dent* 2021;41:711–717.
10. Aoki A, Mizutani K, Schwarz F, et al. Periodontal and peri-implant wound healing following laser therapy. *Periodontol* 2000 2015;68:217–269.
11. Gurpegui Abud D, Shariff JA, Linden E, Kang PY. Erbium-doped:yttrium-aluminum-garnet (Er:YAG) versus scaling and root planning for the treatment of periodontal disease: A single-blinded split-mouth randomized clinical trial. *J Periodontol* 2022;93:493–503.
12. Hakki SS, Berk G, Dundar N, Saglam M, Berk N. Effects of root planing procedures with hand instrument or erbium, chromium:yttrium-scandium-gallium-garnet laser irradiation on the root surfaces: A comparative scanning electron microscopy study. *Lasers Med Sci* 2010;25:345–353.
13. Ting CC, Fukuda M, Watanabe T, Aoki T, Sanaoka A, Noguchi T. Effects of Er,Cr:YSGG laser irradiation on the root surface: Morphologic analysis and efficiency of calculus removal. *J Periodontol* 2007;78:2156–2164.
14. Nevins M, Benfenati SP, Galletti P, et al. Human histologic evaluations of the use of Er,Cr:YSGG laser to decontaminate an infected dental implant surface in preparation for implant reosseointegration. *Int J Periodontics Restorative Dent* 2020;40:805–812.
15. Berglundh T, Armitage G, Araujo MG, et al. Peri-implant diseases and conditions: Consensus report of workgroup 4 of the 2017 World Workshop on the Classification of Periodontal and Peri-Implant Diseases and Conditions. *J Periodontol* 2018;89(suppl 1):s313–s318.
16. Lerario F, Roncati M, Gariffo A, et al. Non-surgical periodontal treatment of peri-implant diseases with the adjunctive use of diode laser: Preliminary clinical study. *Lasers Med Sci* 2016;31:1–6.
17. Sanz M, Chapple IL; Working Group 4 of the VIII European Workshop on Periodontology. Clinical research on peri-implant diseases: Consensus report of Working Group 4. *J Clin Periodontol* 2012;39(suppl 12):202–206.
18. Mizutani K, Aoki A, Coluzzi D, et al. Lasers in minimally invasive periodontal and peri-implant therapy. *Periodontol* 2000 2016;71:185–212.
19. Cobb CM, Low SB, Coluzzi DJ. Lasers and the treatment of chronic periodontitis. *Dent Clin North Am* 2010;54:35–53.



- 
20. Schwarz F, Sculean A, Rothamel D, Schwenzer K, Georg T, Becker J. Clinical evaluation of an Er:YAG laser for non-surgical treatment of peri-implantitis: A pilot study. *Clin Oral Implants Res* 2005;16:44–52.
  21. Strever J, Lee J, Ealick W, et al. Erbium, chromium:yttrium-scandium-gallium-garnet laser effectively ablates single-species biofilms on titanium disks without detectable surface damage. *J Periodontol* 2017;88:484–492.
  22. Kelbauskiene S, Baseviciene N, Goharkhay K, Moritz A, Machiulskiene V. One-year clinical results of Er,Cr:YSGG laser application in addition to scaling and root planing in patients with early to moderate periodontitis. *Lasers Med Sci* 2011;26:445–452.
  23. Mills MP, Rosen PS, Chambrone L, et al. American Academy of Periodontology best evidence consensus statement on the efficacy of laser therapy used alone or as an adjunct to non-surgical and surgical treatment of periodontitis and peri-implant diseases. *J Periodontol* 2018;89:737–742.
  24. Noraian KW, Cobb CM. The efficacy of laser therapy: Commentary on the American Academy of Periodontology Best Evidence Consensus meeting. *J Periodontol* 2018;89:804–806.
  25. Klokkevold PR, Damian A, Pham C, Mallya SM, Lux R. Clinical evaluation of Er,Cr:YSGG laser therapy used as an adjunct to non-surgical treatment of periodontitis: Twelve-month results from a pilot study. *J Periodontol* 2022. Epub ahead of print.
  26. Khoury F, Keeve PL, Ramanauskaite A, et al. Surgical treatment of peri-implantitis—Consensus report of working group 4. *Int Dent J* 2019;69(suppl 2):18–22.
  27. Kesler G, Romanos G, Koren R. Use of Er:YAG laser to improve osseointegration of titanium alloy implants—A comparison of bone healing. *Int J Oral Maxillofac Implants* 2006;21:375–379.